

A "cortico-basal degeneration" - like syndrome as first sign of progressive multifocal leukoencephalopathy

M. VAN ZANDIJCKE and I. DEHAENE

Department of Neurology, AZ St-Jan, Brugge, Belgium

Abstract

We report an unusual case of probable progressive multifocal leukoencephalopathy (PML), who initially presented with a right-sided movement disorder, including upper limb dystonia, tremor, and dyspraxia, reminiscent of corticobasal degeneration. In the further course, the patient developed disorientation, confusion, and bradyphrenia. The appearance of white matter MRI lesions as well as a positive PCR test result for JC-virus in the cerebrospinal fluid finally led to the correct diagnosis.

Key words : Corticobasal degeneration ; movement disorder ; parkinsonism ; progressive multifocal leukoencephalopathy (PML).

Introduction

Corticobasal ganglionic degeneration is a degenerative disorder of the central nervous system, characterised by the asymmetric development of cortical (limb apraxia) and basal ganglionic signs (dystonia, parkinsonism) (Riley *et al.*, 1990 ; Rinne *et al.*, 1994 ; Litvan *et al.*, 1997 ; Wenning *et al.*, 1998). We report a patient with unilateral upper limb dystonia, tremor and dyspraxia, in whom the diagnosis of corticobasal degeneration was first suspected. Eventually, a diagnosis of progressive multifocal leukoencephalopathy (PML) was made. An extrapyramidal syndrome is a rare presenting symptom of PML ; some cases have been reported before (Ledoux *et al.*, 1989 ; Singer *et al.*, 1993 ; Werring and Chaudhuri, 1996 ; Bhatia *et al.*, 1996).

Case Report

A 73-year-old man had progressive writing difficulty since January 1996. He also noted some clumsiness in dressing and in buttoning his shirt. Medical history mentioned coronary sclerosis and chronic atrial fibrillation. In 1985, he underwent coronary artery bypass grafting. In 1990, a chronic lymphatic leukaemia was diagnosed ; the patient

was treated with chlorambucil and monthly intravenous immunoglobulins.

Neurological examination in January 1996 showed slowing of finger movements of the right hand. There was hypokinesia in the right upper limb ; alternating movements of the right arm were performed with difficulty. Muscle strength, sensation, and ocular movements were normal. Visual fields were full. There was no rigidity. No pyramidal signs could be elicited. Magnetic resonance imaging (MRI) of the brain showed some small hyperintensities in the white matter of both hemispheres on T2-weighted images ; they were interpreted as small ischaemic lesions.

In February 1996, a rest and positional tremor of the right hand appeared. The patient had also some 'apractic' complaints : at table, he could no longer use his knife and fork simultaneously. Clinical examination confirmed the existence of apraxia : the patient had difficulties in performing motor tasks with his right arm and hand, that were disproportionate to his akinesia. There was no alien hand phenomenon ; myoclonus was absent. Treatment with levodopa (combined with a decarboxylase-inhibitor) was given at a dose of 300 mg first, later 600 mg a day, without any clinical effect.

In June 1996, trembling and hypokinesia also developed in the left arm. A Tc 99m-HMPAO - single photon emission tomographic scan of the brain showed right frontotemporal hypoperfusion. A therapeutic trial with trihexyphenidil was started without any result.

In November 1996, a no - no head tremor appeared. The hypokinesia spread to the left lower limb. Neurologic examination now showed evident akinesia with gait ignition failure and blockings. There was dystonic facial grimacing and dystonic posturing of the right arm. An irregular, coarse tremor of the head and right upper limb was observed. Ocular movements (saccades and smooth pursuit) still were normal. Treatment with pergolide 3 mg a day produced some symptomatic improvement.

In April 1997, the patient became confused with day - night inversion. He was disoriented in time

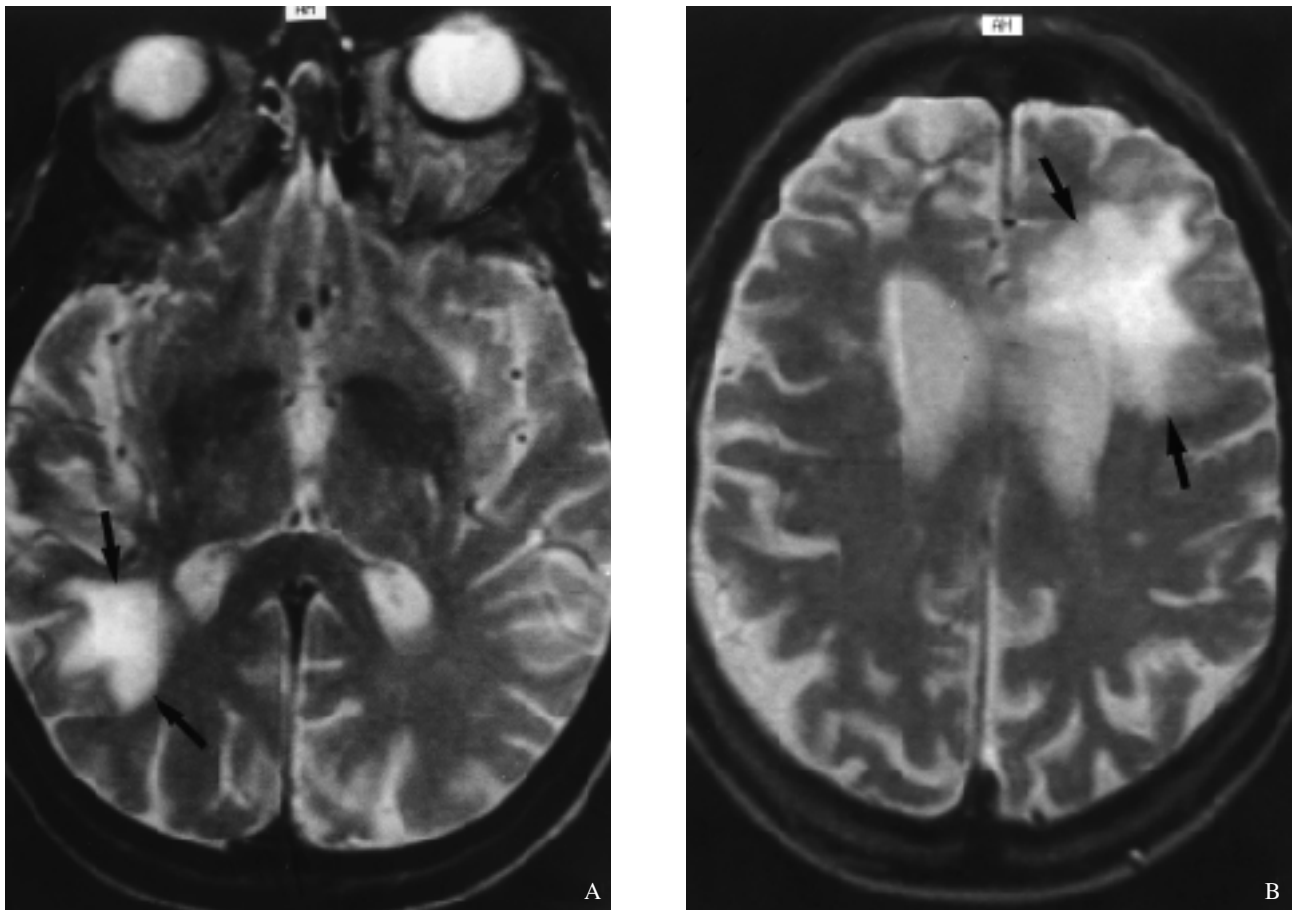


FIG. 1. — Axial T2-weighted spin-echo MR images (13/05/1997).

(A) : A large hyperintense lesion is present in the white matter, posterolateral to the trigone of the right lateral ventricle. The abnormal signal intensity extends to the peripheral white matter ; the cortical grey matter is spared. The basal ganglia are not involved.

(B) : A high signal intensity lesion can be seen anterolateral to the left lateral ventricle, again involving white matter from the periventricular region to the periphery.

and space ; sometimes, he was disinhibited and showed psychomotor agitation. Most of the time, however, he was bradykinetic and bradyphrenic. A second MRI of the brain on 13/05/97 (figure) showed two hyperintense white matter lesions on T2-weighted images, extending to the grey-white matter junction, respectively in the left frontal and in the right parietal lobe. There was no mass effect nor enhancement after Gadolinium administration. Cytochemical analysis of cerebrospinal fluid (CSF) including protein electrophoresis, was normal ; there was no evidence of increased intrathecal IgG synthesis. A polymerase chain reaction (PCR) test for JC-virus on CSF was positive. The patient died on 03/06/97 ; authorisation to perform an autopsy was not obtained.

Discussion

Corticobasal degeneration is characterised by cortical sensory loss, focal reflex myoclonus, limb dystonia, “alien limb” phenomenon, apraxia, rigidity, postural instability, and akinesia ; these signs develop with a striking asymmetry. Unilateral arm

clumsiness is the most common initial symptom. The best predictors for a correct clinical diagnosis are limb dystonia, ideomotor apraxia, myoclonus, and an asymmetric akinetic-rigid syndrome, while gait and balance disturbances occur later on (Riley *et al.*, 1990 ; Rinne *et al.*, 1994 ; Litvan *et al.*, 1997 ; Wenning *et al.*, 1998). In our case, the diagnosis of corticobasal degeneration was first considered, owing to the unilateral onset of parkinsonism unresponsive to levodopa, associated with upper limb apraxia. When the patient rapidly developed intellectual and personality changes, and the second MRI examination was performed, a diagnosis of PML was suspected.

PML is an opportunistic viral infection of the central nervous system, affecting and causing symptoms referable to multiple white matter pathways in the brain (Bale, 1991). It almost always occurs in individuals who have underlying diseases that alter their cell-mediated immunity or who are iatrogenically immunosuppressed ; rare cases have been described in patients without immunosuppressing disease. Patients are generally afebrile and have no other signs of systemic infection.

Neurologic progression generally occurs over weeks to months, though occasional patients survive for years (Richardson, 1982).

PML is a diffuse, asymmetric disease that involves, in descending order, the cerebral hemispheres, cerebellum, brainstem, and spinal cord (Stoner *et al.*, 1988). Typically, patients present with prominent homonymous hemianopia and monoparesis or hemiparesis. Insidious intellectual deterioration is a prominent early manifestation, presenting as personality changes and progressing to blunted intellect, frank dementia, and finally coma. Though patients usually present with cerebral symptoms, a minority of cases present with brainstem or cerebellar involvement or seizures (Holman *et al.*, 1998). Extrapyrarnidal involvement as evidenced by bradykinesia, rigidity, or parkinsonism is rare: it was the presenting feature in only 2.8 % of cases in a series of 69 pathologically confirmed cases and 40 virologically and pathologically confirmed cases of PML (Brooks and Walker, 1984).

Some cases of PML presenting as an extrapyramidal syndrome have been reported before. Ledoux *et al.* (1989) described a patient with right hemidystonia due to a PML lesion of the opposite basal ganglia, visualised by MRI. Singer *et al.* (1993) reported a young girl with HIV-related PLM, who presented with a rapidly progressive akinetic-rigid syndrome and dystonic facial grimacing. Werring and Chaudhuri (1996) reported another patient with HIV-related PML who rapidly progressed to a levodopa-unresponsive severe akinetic-rigid syndrome; this patient exhibited some features (myoclonus, alien limb phenomenon) suggestive of corticobasal degeneration. In the case report of Bhatia *et al.* (1996), the diagnosis of corticobasal degeneration was also considered; the disease lasted 10 years and the diagnosis of PML was confirmed at post-mortem.

The diagnosis of PML can only be made with certainty by histopathological diagnosis of the brain. However, neuroradiological features may be extremely suggestive in many cases and polymerase chain reaction (PCR) seems to be a reliable technique for demonstrating viral genome in the CSF. MRI is more sensitive at detecting the number and extent of lesions of PML than CT, and reveals focal or multifocal hypointense lesions on T1 and high-signal intensity lesions on T2. MRI lesions are homogeneous, have indistinct margins, and have no mass effect or gadolinium enhancement, though mild enhancement has been described (Sweeney *et al.*, 1993; Whiteman *et al.*, 1993). Lesions can follow the grey-white junction, producing a characteristic "scalloped" appearance. Diagnostic tests using PCR techniques in cerebrospinal fluid are becoming increasingly sensitive (up to 92%) and specific at detecting JC viral DNA (McGuire *et al.*, 1995; Perrons *et al.*, 1996).

Although definitive diagnosis of PML requires examination of brain tissue by brain biopsy or at autopsy (Bale, 1991), we believe that in our patient the diagnosis of PML can be made with confidence. He was chronically immunosuppressed as a result of chronic lymphatic leukaemia; he received intravenous immunoglobulins at regular intervals. The disease course was somewhat long for PML, but prolonged survival exceeding 12 months from symptom onset has been reported (Berger *et al.*, 1998). The full-blown clinical picture consisted of intellectual deterioration and personality changes, as classically described. The appearance of the two lesions on the second MRI was very suggestive for PML. Finally, the PCR on CSF detected JC virus DNA. Our case adds to the growing clinical experience that a syndrome resembling corticobasal degeneration can sometimes be the presenting feature of PML.

Acknowledgement

The authors thank Jan Casselman, Ph.D., M.D., for kindly providing the MR images.

REFERENCES

- BALE J. Encephalitis and other virus-induced neurologic disorders. In: *Clinical neurology*. JOYNT R. (ed.). 1991 rev. ed. Philadelphia: Lippincott, 1991: 52-5.
- BERGER J. R., LEVY R. M., FLOMENHOFT D., DOBBS M. Predictive factors for prolonged survival in acquired immunodeficiency syndrome-associated progressive multifocal leukoencephalopathy. *Ann. Neurol.*, 1998, **44**: 341-349.
- BHATIA K. P., MORRIS J. H., FRACKOWIAK R. S. J. Primary progressive multifocal leukoencephalopathy presenting as an extrapyramidal syndrome. *J. Neurol.*, 1996, **243**: 91-5.
- BROOKS B., WALKER D. Progressive multifocal leukoencephalopathy. *Neurol. Clin.*, 1984, **2**: 299-313.
- HOLMAN R. C., TOROK T. J., BELAY E. D., JANSSEN R. S., SCHONBERGER L. B., 1996, **11**: 758-761. Progressive multifocal encephalopathy in the United States, 1979-1994: increased mortality associated with HIV infection. *Neuroepidemiology*, 1998, **17**: 303-309.
- LEDOUX S., LIBMAN I., ROBERT G., JUST N. Progressive multifocal leukoencephalopathy with grey matter involvement. *Can. J. Neurol. Sci.*, 1989, **16**: 200-202.
- LITVAN I., AGID Y., GOETZ C., JANKOVIC J., WENNING G. K. *et al.* Accuracy of the clinical diagnosis of corticobasal degeneration: a clinicopathological study. *Neurology*, 1997, **48**: 119-125.
- MCGUIRE D., BARHITE S., HOLLANDER H., MILES M. JC virus DNA in cerebrospinal fluid of human immunodeficiency virus-infected patients: predictive value for progressive multifocal leukoencephalopathy. *Ann. Neurol.*, 1995, **37**: 395-9.
- PERRONS C. J., FOX J. D., LUCAS S. B., BRINK N. S., TEDDER R. S., MILLER R. F. Detection of polyoma

- viral DNA in clinical samples from immunocompromised patients : correlation with clinical disease. *J. Infect.*, 1996, **32** : 205-9.
- RICHARDSON E. Progressive multifocal leukoencephalopathy 30 years later. *N. Engl. J. Med.*, 1982, **318** : 315-7.
- RILEY D. E., LANG A. E., LEWIS A., RESCH L., ASHBY P. *et al.* Cortical-basal ganglionic degeneration. *Neurology*, 1990, **40** : 1203-1212.
- RINNE J. O., LEE M. S., THOMPSON P. D., MARSDEN C. D. Corticobasal degeneration. A clinical study of 36 cases. *Brain*, 1994, **117** : 1183-1196.
- SINGER C., BERGER J. R., BOWEN BC, BRUCE JH, WEINER WJ. Akinetic-rigid syndrome in a 13-year-old girl with HIV-related progressive multifocal encephalopathy. *Mov. Disord.*, 1993, **8** : 113-116.
- STONER G., WALKER D., WEBSTER H. Age distribution of progressive multifocal leukoencephalopathy. *Acta Neurol. Scand.*, 1988, **78** : 307-12.
- SWEENEY B., MILLER R., HARRISON M. Progressive multifocal leucoencephalopathy. *Br. J. Hosp. Med.*, 1993, **50** : 187-92.
- WENNING G., LITVAN I., JANKOVIC J., GRANATA R., MANGONE C. A. *et al.* Natural history and survival of 14 patients with corticobasal degeneration confirmed at postmortem examination. *J. Neurol. Neurosurg. Psychiatry*, 1998, **64** : 184-189.
- WERRING D. J., CHAUDHURI K. R. Human immunodeficiency virus-related progressive multifocal encephalopathy presenting with an akinetic rigid syndrome. *Mov. Disord.*, 1996, **11** : 758-761.
- WHITEMAN M., POST M., BERGER J., TATE L., BELL M., LIMONTE L. Progressive multifocal leukoencephalopathy in 47 HIV-seropositive patients : neuroimaging with clinical and pathologic correlation. *Radiology*, 1993, **187** : 233-40.

M. VAN ZANDIJCKE
Department of Neurology,
Algemeen Ziekenhuis St-Jan AV,
B-8000 Brugge (Belgium).